



Cutaneous wound healing in castrated and uncastrated rabbits: Comparative study

Falah Mahmood Hameed

Surgery and Obstetric Department, Veterinary Medicine Faculty College, University of Kerbala, Karbala, Iraq.

*Corresponding author e- Email: falah.m@uokerbala.edu.iq

<https://doi.org/10.59658/jkas.v11i2.1847>

Received:

Feb. 19, 2024

Accepted:

Apr. 20, 2024

Published:

June 10, 2024

Abstract

The purpose of this research is to examine the effects of testosterone on rabbits' full-thickness skin wounds. A full-thickness (2 cm²) wound was produced in the dorsal back region of sixteen (16) mature male rabbits that were in good clinical condition and weighed between (1.3 and 1.8 kg). Administration intramuscularly of a mixture of 5mg/kg of xylazine hydrochloride 35mg/kg of ketamine hydrochloride, and 1 mg/kg of Diazepam. At 3, 7, 14, and 21 days after the formation and treatment of the wound, each group was divided into 4 subgroups (two wounds/subgroup) for the purpose of clinical evaluation. The wound healing rate was monitored for 21 days. The level of serum testosterone in both groups was also examined at the same time. The results revealed, clinically, that the rate of skin healing in castrated rabbits was quicker than in non-castrated rabbits. In addition, the results revealed that castrated groups have enhanced cellularity and increased vasculature, which is superior to those in non-castrated groups. Conclusion: The clinical findings confirmed the effects of testosterone on cutaneous wound healing.

Keywords: wound healing; rabbits; testosterone; non-castrated; Cutaneous.

Introduction

Remodeling, proliferation, inflammation, and hemostasis are the overlapping and intricately coordinated phases of acute wound healing that are brought on by tissue damage. When the integrity of the skin is compromised, platelets commence hemostasis by forming fibrin clots. In order to draw fibroblasts and macrophages to the area of tissue damage, platelets also produce a variety of wound-healing mediators [1].

Castration is the term for a procedure that ends the testes' ability to function, resulting in sterilization [2]. The reasons for castration vary depending on the procedure's purpose, which can include reducing male hormone and sperm production, preventing mating after puberty, producing animals that are less aggressive and easier to handle, preventing undesired pregnancies and the breeding of young females before they are of an appropriate age and body size for parturition and pregnancy, and lessening smell in goat males [3].



The primary source of the steroid hormone testosterone is the testes; minor amounts are also produced by the adrenal glands and blood. It contains compounds that are both androgenic and estrogenic, and they complement one another in their effects on skin survival and revascularization [4]. Testosterone is thought to enhance overall wound healing [5]. Testosterone can either be converted to the nonaromatizable androgen dihydrotestosterone or stimulate the receptor of androgen. or it can aromatize into 17β estradiol, which then stimulates the estrogen receptor [6,7]. All anabolic drugs have some degree of androgenic effects. The development of sex glands in males, the pattern of growth of male hair, a rise in desire, and a role in spermatogenesis are examples of androgenic effects [8]. Much research has been done on how testosterone deficiency affects cutaneous wound healing, primarily in large animals; hence, the Aim of the study is to explain the effects of testosterone on cutaneous wound healing.

Consequently, the goal of this study was to find out how dietary pomegranate seed powder mixed with *Saccharomyces cerevisiae* affected the lipid profile of a local male lamb.

Materials and Methods

Sixteen male adult rabbits in the research, weighing between (1.3 and 1.8 kg) were divided into two groups, with eight rabbits in each group. During the time of the study, At the University of Kerbala's Faculty of Veterinary Medicine, the animals were kept in different cages, in a typical setting with regard to nutrition, climate, and management.

Animals Preparation and Anesthesia

Water was withheld for five hours, and food for six to twelve hours before anaesthesia. The dorsal back region should be cleaned and shaved before general anaesthesia is induced with a pre-anaesthetic dose of 1 mg/kg body weight. After 10 minutes, xylazine (10 mg/kg B.W.) and ketamine (50 mg/kg B.W.) are injected intramuscularly [9]. The rabbits were placed in a ventral recumbent position while the aseptic surgery was being performed on the dorsal aspect, or back, of the animal.

Surgical Operation

In the dorsal back region of each animal, a single, full-thickness skin incision measuring (2 x 2) was made. The animals were randomly divided into two equal groups: the castrated group (A) and the non-castrated group (B).

Evaluations

Throughout the course of the three-week examination, the following clinical assessments of the wound healing developments were made for the control and treatment of wounds:

Clinical Evaluations

All animals underwent a thorough clinical evaluation every three days during the examination. To visualize the wound margin, all wounds were photographed digitally after the area had been neatly shaved. Using saline, the scab was carefully removed from each site to improve the visibility of the granulation tissue and epithelization area.

Blood sampling

At 3, 7, 14, and 21 days following the start of the study, blood samples were taken directly from the heart in both groups while maintaining perfect aseptic conditions. The serum was separated and stored at -20°C for 10 minutes at 3000 rpm centrifugation; then testosterone levels could be measured.

Results and Discussion

Assessing the cutaneous wounds clinically

All operated rabbits recovered from surgical procedures without apparent complications. They had a good appetite and urinated directly after recovering from sedation and anaesthesia in a few hours post-surgery. None of the Castrated rabbits which were utilized in the study showed indications of pain or changes in eating or drinking patterns and became calmer than non-castrated rabbits.

The wound edges were clipped, derided, and thoroughly cleansed with 0.9% normal saline to achieve a decontaminated wound. The final flushing was spiked with diluted antiseptic solution (povidine) and then anesthetized generally. Antibiotics are used locally, and the wounds leave without being sutured. A sterile bandage was fixed on it for three days and then removed. Finally, systemic antibiotics were used for five days. The non-Castrated group's wounds healed more slowly and required roughly three weeks to fully recover. Whereas the castration group's wounds healed fully in fourteen days and had ideal wound margins (Figure 2).

Concentration of serum testosterone

The value of testosterone concentration was recorded significant differences $P \leq 0.0001$ between 3-day time (5.27 ± 0.48 ng/ml) and remaining periods. Furthermore, The values in animals connected to revealed a significant difference ($P \leq 0.0001$) in the castration group, especially at 3, 14 and 21 days. In contrast, obscure of significance ($P \geq 0.0001$) between 7 and 14 days. During the duration of the examination, the level of testosterone decreased dramatically, reaching its lowest value of 0.6083 ng/ml 21 days after castration (Table 1 and Figure 1).

Table (1): Serum testosterone concentration Mean values (ng/ml) at various time points for the castration and control groups

Period	Non-castration group (mean)	Castration group (mean)	Adjusted P Value	Summary
3 day	4.300	3.000	<0.0001	****
7 day	4.100	2.083	<0.0001	****
14 day	4.033	1.517	<0.0001	****
21 day	4.240	0.6083	<0.0001	****

Letters (***) refer to significant differences $P \leq 0.05$ among periods in both groups.

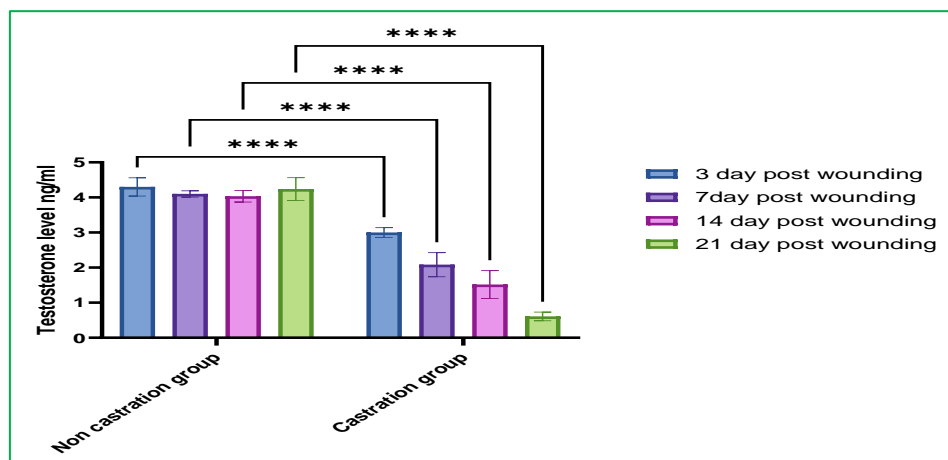


Figure (1): Mean values of serum testosterone concentration (ng/ml) in castration and non-castration groups at different periods.

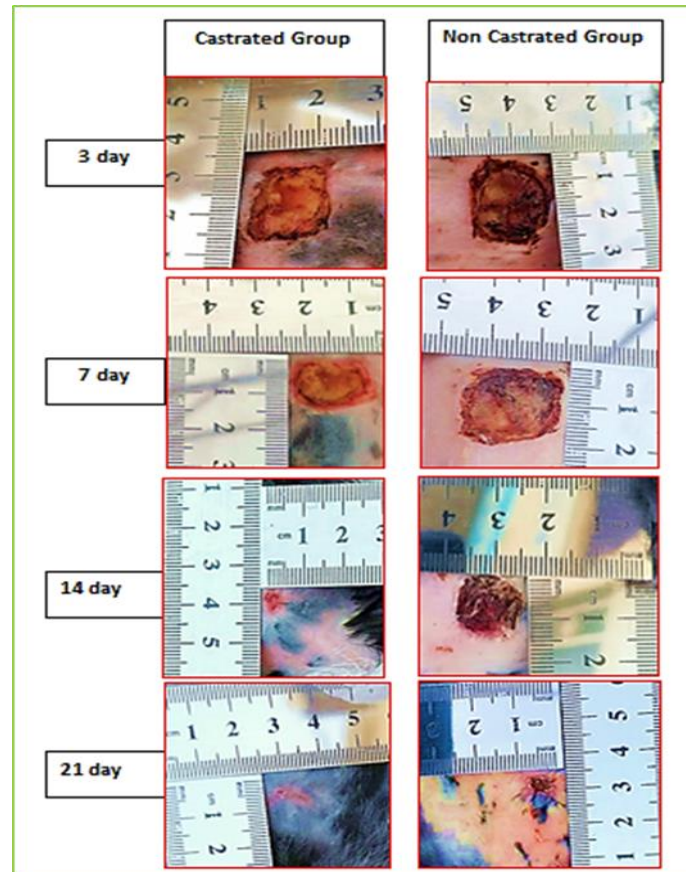


Figure (2): The total wound healing observed in the castrated groups and non-castrated groups was clearly different, at 3rd, 7th, 14th and 21th days post-wounding.

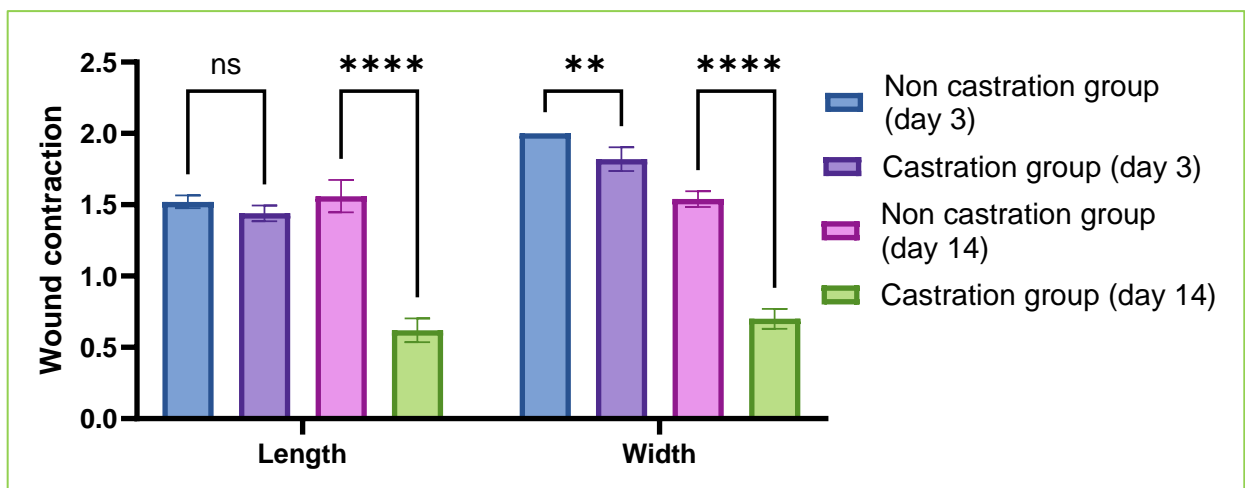


Figure (3): Effect of testosterone and day in the wound contraction's width and length in the castrated groups and non-castrated groups at 7th and 14th days post-wounding

Table (2): Effect of testosterone and day in Length and Width of Wound contraction in both groups.

period/wound contraction	Non-Castration group	Castration group	Adjusted P Value	Summary
Length (day 3)	1.520	1.440	0.2932	ns
Length (day 14)	1.560	0.6200	<0.0001	****
Width: (day 3)	2.000	1.820	0.0013	**
Width: (day 14)	1.540	0.7000	<0.0001	****

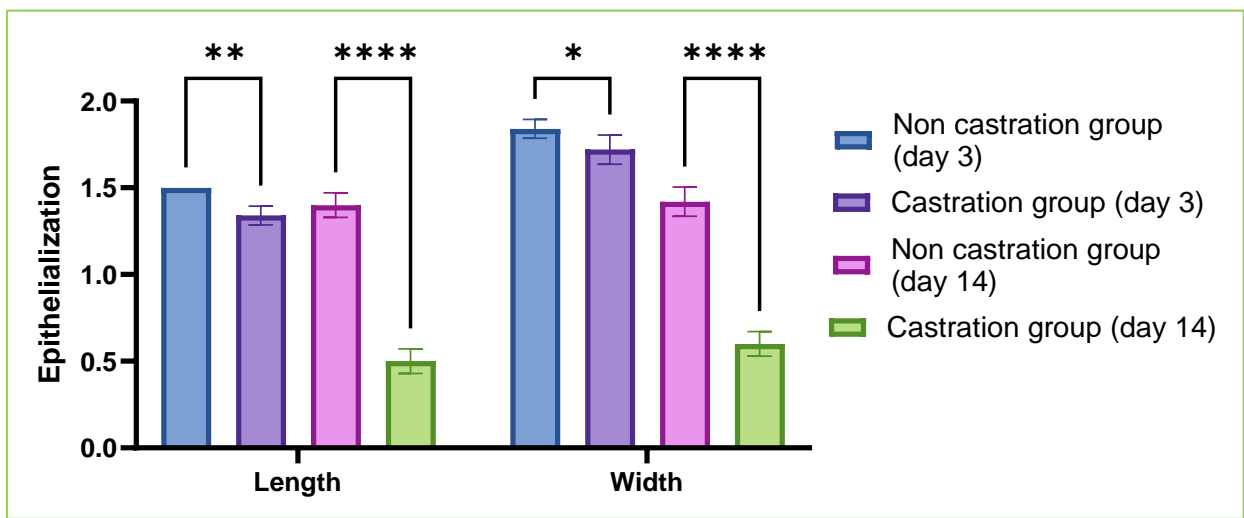


Figure (4): Effect of testosterone and day in Length and Width of Wound epithelialization in the castrated groups and non-castrated groups at 7th and 14th days post-wounding.

Table (3): Effect of testosterone and day in Length and Width of Wound epithelialization in both groups

period / Epithelialization	Non castration group	Castration group	Adjusted P Value	Summary
Length (day 3)	1.500	1.340	0.0023	**
Length: (day 14)	1.400	0.5000	<0.0001	****
Width: (day 3)	1.840	1.720	0.0287	*
Width: (day 14)	1.420	0.6000	<0.0001	****



The results showed important variations in the rates of wound healing between the two groups. Delayed wound healing has been linked to a number of processes [10, 11], and it's likely that the circulating sex steroid hormone balance is also off, particularly in older adults. [12] In addition, sex steroid hormones have a significant impact on skin physiology [13, 14].

Estrogens and androgens play key roles in wound healing in the skin by promoting the growth and epithelial cell development, in addition to fibroblast and skin immune cell activities [15]. The wounds of castrated rabbits healed more quickly than those of non-castrated rabbits due to a quicker course of wound contraction (figure 1). When comparing castrate to non-castrate, the levels of estrogen and testosterone also rose and fell, respectively. This is consistent with a study [16] that found that, in castrated mice, faster healing was linked to higher local levels of matrix collagen.

Previous research has shown that castrating male mice to lower the level of androgens in the blood accelerates the healing of skin wounds by decreasing the inflammatory reaction locally and increasing extracellular matrix deposition (ECM) [17,18]. The restoration of androgens in orchietomized mice counteracted the wound-healing effect of castration [17,18]. In animals lacking the androgen receptor (AR), as well as in chemically blocking the conversion of testosterone to DHT, delayed wound healing has also been documented [17, 18,19]. According to these researches, androgens impede the healing of cutaneous wounds by producing more TNF and IL-6, reducing collagen deposition and re-epithelialization wound [17, 18,19].

Curiously, endogenous testosterone may, according to recent research, induce inflammation and impede wound healing [16,20] discovered that testosterone improved male rats' depressive-like behavior. [21] showed that pharmacological castration regimens and serum testosterone levels were correlated. An additional investigation revealed Testicular Leydig cells release testosterone, the primary androgen circulating in male mammals. Following testicular production, 5α -reductase enzymes convert a modest percentage (5~10%) of circulating testosterone to the more potent androgen dihydrotestosterone (DHT) [22, 23]. Previous research has shown that castrating male mice to lower the level of androgens in the blood accelerates the healing of cutaneous wounds by decreasing the local inflammatory response and increasing the deposition of extracellular matrix (ECM) [24, 25]. In orchietomized mice, the restoration of androgens counteracted the effect of castration on wound healing [24, 25]. Additionally, it has been documented that delayed wound healing occurs in genetically androgen receptor (AR) deficient animals or following pharmaceutical blockage of testosterone conversion to DHT [24, 26]. These investigations show that androgens impede skin wound healing by producing more TNF and IL-6, decreasing collagen deposition and re-epithelialization wound [24, 25, 26].

The current study also supports a study by [27] which found that mice treated with dihydrotestosterone had a higher rate of recovery, especially in the early phases of the healing process (days 3–14). Dihydrotestosterone affected keratinocyte cell proliferation, ECM formation, and local inflammation, which all contributed to these effects.



Testosterone can either [6] be converted to the nonaromatizable androgen dihydrotestosterone stimulates receptor of androgen, or [7] be aromatized into 17β -estradiol. Additionally, the present investigation is consistent with a study [28] that showed male mouse castration accelerates the healing of cutaneous wounds and is linked to enhanced matrix deposition, a tamped-down inflammatory response, and both. We showed, using a hairless mouse model, that these impacts on the healing rate were not caused by increased proliferation of hair follicles as a result of castration.

This study suggests that wounds in castrate rabbits heal more quickly than in non-castrate rabbits, which will increase the likelihood of quicker surgical wound healing for veterinary surgeons treating castrate animals.

References

1. Singer AJ, Clark RA. (1999). Cutaneous wound healing. *N Engl J Med*, 341(10), 738-746.
2. Fisher, A. D., Knight, T. W., Cosgrove, G. P., Death, A. F., Anderson, C. B., Dugan-zich, D. M., & Matthews, L. R. (2001). Effects of surgical or banding castration on stress responses and behaviour of bulls. *Australian veterinary journal*, 79(4), 279–284.
3. Burciage RL, Step DL, Holland BP, McCurdy MP, Krehbiel CR (2006). Castration in goats: Technique and animal welfare issues. *Compendium of Continuing Education for the Practicing Veterinarian*, 24(9), 512-515.
4. Chenu, C., Adlanmerini, M., Boudou, F., Chantalat, E., Guihot, A. L., Toutain, C., Raymond-Letron, I., Vicendo, P., Gadeau, A. P., Henrion, D., Arnal, J. F., & Lenfant, F. (2017). Testosterone prevents cutaneous ischemia and necrosis in males through complementary estrogenic and androgenic actions. *Arteriosclerosis, thrombosis, and vascular biology*, 37(5), 909–919.
5. Demling R. H. (2005). The role of anabolic hormones for wound healing in catabolic states. *Journal of Burns and Wounds*, 4, e2.
6. Toutain, C. E., Brouchet, L., Raymond-Letron, I., Vicendo, P., Bergès, H., Favre, J., Fouque, M. J., Krust, A., Schmitt, A. M., Chambon, P., Gourdy, P., Arnal, J. F., & Lenfant, F. (2009). Prevention of skin flap necrosis by estradiol involves reperfusion of a protected vascular network. *Circulation research*, 104(2), 245–254.
7. Suzuki, S., Brown, C. M., & Wise, P. M. (2009). Neuroprotective effects of estrogens following ischemic stroke. *Frontiers in neuroendocrinology*, 30(2), 201–211.
8. Pelletier G. (2000). Localization of androgen and estrogen receptors in rat and primate tissues. *Histology and histopathology*, 15(4), 1261–1270.
9. Albozachri JMK, Hameed FM, AL-Tomah HM, Muhammad HA (2017). Evaluation of two general anesthetic regime by use xylazine and ketamine with atropine and diazepam in rabbits. *University of Kerbala*, 15(1), 21-30.
10. Brem, H., & Tomic-Canic, M. (2007). Cellular and molecular basis of wound healing in diabetes. *The Journal of Clinical Investigation*, 117(5), 1219–1222.



11. Taylor, R. J., Taylor, A. D., & Smyth, J. V. (2002). Using an artificial neural network to predict healing times and risk factors for venous leg ulcers. *Journal of Wound Care*, 11(3), 101–105.
12. Hardman, M. J., & Ashcroft, G. S. (2008). Estrogen, not intrinsic aging, is the major regulator of delayed human wound healing in the elderly. *Genome Biology*, 9(5), R80.
13. Zouboulis, C. C., Chen, W. C., Thornton, M. J., Qin, K., & Rosenfield, R. (2007). Sexual hormones in human skin. *Hormone and Metabolic Research = Hormon- und Stoffwechselforschung = Hormones et Metabolisme*, 39(2), 85–95.
14. Dao, H., Jr, & Kazin, R. A. (2007). Gender differences in skin: a review of the literature. *Gender Medicine*, 4(4), 308–328.
15. Strudwick, X., Powell, B., & Cowin, A. (2006). Role of Sex Hormones in Acute and Chronic Wound Healing. *Primary Intention: The Australian Journal of Wound Management*, 14(1), 35–38.
16. Ashcroft, G. S., & Mills, S. J. (2002). Androgen receptor-mediated inhibition of cutaneous wound healing. *The Journal of Clinical Investigation*, 110(5), 615–624.
17. McCrohon, J. A., Jessup, W., Handelsman, D. J., & Celermajer, D. S. (1999). Androgen exposure increases human monocyte adhesion to vascular endothelium and endothelial cell expression of vascular cell adhesion molecule-1. *Circulation*, 99(17), 2317–2322.
18. Gilliver, S. C., Ashworth, J. J., Mills, S. J., Hardman, M. J., & Ashcroft, G. S. (2006). Androgens modulate the inflammatory response during acute wound healing. *Journal of Cell Science*, 119(Pt 4), 722–732.
19. Lai, J. J., Lai, K. P., Chuang, K. H., Chang, P., Yu, I. C., Lin, W. J., & Chang, C. (2009). Monocyte/macrophage androgen receptor suppresses cutaneous wound healing in mice by enhancing local TNF-alpha expression. *The Journal of Clinical Investigation*, 119(12), 3739–3751.
20. Carrier, N., & Kabbaj, M. (2012). Extracellular signal-regulated kinase 2 signaling in the hippocampal dentate gyrus mediates the antidepressant effects of testosterone. *Biological Psychiatry*, 71(7), 642–651.
21. Ko, D. H., Lee, K., Jeon, S. H., Song, S. H., Yun, Y. M., Chun, S., Kim, H. S., Kim, J. Y., In, M. K., & Song, J. (2016). Simultaneous Measurement of Serum Chemical Castration Agents and Testosterone Levels Using Ultra-Performance Liquid Chromatography-Tandem Mass Spectrometry. *Journal of Analytical Toxicology*, 40(4), 294–303.
22. Azzouni, F., Godoy, A., Li, Y., & Mohler, J. (2012). The 5 alpha-reductase isozyme family: A review of basic biology and their role in human diseases. *Advances in Urology*, 2012, 530121.
23. Handelsman, D. J. (2016). *Androgen Physiology, Pharmacology, and Abuse*. Elsevier: Philadelphia, PA, USA.
24. Ashcroft, G. S., Lei, K., Jin, W., Longenecker, G., Kulkarni, A. B., Greenwell-Wild, T., Hale-Donze, H., McGrady, G., Song, X. Y., & Wahl, S. M. (2000).



- Secretory leukocyte protease inhibitor mediates non-redundant functions necessary for normal wound healing. *Nature Medicine*, 6(10), 1147–1153.
25. Gilliver, S. C., Ashworth, J. J., & Ashcroft, G. S. (2007). The hormonal regulation of cutaneous wound healing. *Clinics in Dermatology*, 25(1), 56–62.
26. Wang, Y., Simanainen, U., Cheer, K., Suarez, F. G., Gao, Y. R., Li, Z., Handelsman, D., & Maitz, P. (2016). Androgen actions in mouse wound healing: Minimal in vivo effects of local antiandrogen delivery. *Wound Repair and Regeneration: Official Publication of the Wound Healing Society [and] the European Tissue Repair Society*, 24(3), 478–488.
27. Shi, H., Lo, T.-H., Ma, D., Condor, B., Lesmana, B., Parungao, R. J., Tsai, K. H.-Y., Kim, S., Chen, H.-T., Silveira, P. A., et al. (2020). Dihydrotestosterone (DHT) Enhances Wound Healing of Major Burn Injury by Accelerating Resolution of Inflammation in Mice. *International Journal of Molecular Sciences*, 21(17), 6231.
28. Gilliver, S. C., Wu, F., & Ashcroft, G. S. (2003). Regulatory roles of androgens in cutaneous wound healing. *Thrombosis and Haemostasis*, 90(6), 978–985).