



Investigation of hepatoprotective effect of aqueous extract of *Callistemon viminalis* (AECV) in paracetamol-induced liver toxicity in male rats

Raeed Altaee^{1*}

¹Physiology, Biochemistry and Pharmacology Department, College of Veterinary Medicine, University of Kerbala, Karbala, Iraq

*Corresponding author e-mail: raeed.a@uokerbala.edu.iq

Received:

Dec. 16, 2022

Accepted:

Jan. 02, 2023

Published:

Mar. 23, 2023

Abstract

The current study was performed to investigate the hepatoprotective potential of *Callistemon viminalis* (AECV) on paracetamol –induced liver damage in male rats. Twenty-four male Wister rats (150–200 gm) were divided into 4 groups (6 animals each). Paracetamol was given at a dose of 2g/kg once daily for one week to induce liver injury, while AECV was administered via oral gavage at a dose of 200mg/kg B.W. for 4 weeks. Silymarin was given orally as reference hepatoprotective drug at a dose of 100mg/kg B.W. Liver enzymes such as ALT, AST, ALP, and total bilirubin were used to determine the level of hepatic injury recovery. SOD and CAT were measured as antioxidant enzymes. Both AECV and silymarin were successful in preventing the liver damage caused by paracetamol in male rats. The extract's hepatoprotective properties were demonstrated by a significant decrease in the blood enzymes ALT, AST, ALP, and TB and an increase in the antioxidant enzymes SOD and CAT.

Keywords: Aqueous extract of *Callistemon viminalis*, Hepatoprotective activity, Hepatotoxicity, Paracetamol, liver enzymes.

Introduction

The liver is regarded as a major organ that participates in numerous biochemical and physiological processes, these include the processes involved in maintaining the regulating processes of biological systems, growth, energy, and nutrient supply, as well as the biotransformation of both endogenous and exogenous substances, including drugs and xenobiotics [1, 2]. Diseases including cirrhosis, fatty liver, and jaundice are among the illnesses that have caused public health concerns around the world. Basically, hepatotoxic substances such as alcohol, narcotics, and viral diseases are a leading cause of hepatic injury [1, 3]. Despite the fact that cirrhosis affects 4.5 to 9.5% of individuals worldwide and chronic liver disease affects 18.5%, more than 2 million people pass away every year [4]. This might be attributed to the limitations of conventional or synthetic drugs, which can result in harmful adverse effects [5]. Consequently, numerous medicinal plants have been tested in order to determine their regeneration and hepatoprotective properties [3]. Interestingly, it has been reported that potential hepatoprotective activity originated from 101 plants and was attributed to their constituents, i.e., more than 160 phytochemicals [6], These medicinal plants



are considered to be a crucial source of medication for liver conditions such as cirrhosis, hepatitis, and appetite loss [7].

Callistemon viminalis is a member of the family Myrtaceae of plants used for medicine and is widely dispersed around the globe, although it is more common in tropical Asia, South America, Australia, Sri Lanka, and India [8]. It is relevant to note that *Callistemon viminalis* leaf has medicinal importance and shows a variety of actions, including antifungal, antibacterial, antidiabetic, calcium channel blocking, free radical scavenging, and antithrombotic effects, as well as antioxidant and hepatoprotective activity [9,10]. Thus, this remedy plant is effective for treating respiratory problems, skin diseases, and stomachaches [11]. This is due to a variety of phytochemicals belonging to various chemical classes, including flavonoids, phenolic derivatives, terpenes, and other miscellaneous compounds [12].

Paracetamol is well known as an analgesic and a non-steroidal anti-inflammatory drug (NSAID). Due to its availability, and a perception that it has a decent safety record at therapeutic doses, it can seriously harm the liver in chronic abusers [13]. The current study was conducted to examine the hepatoprotective effects of *Callistemon viminalis* in rat induced paracetamol toxicity.

Materials and Methods

Preparation of plant material

Fresh *Callistemon viminalis* leaves (Figure 1) were obtained between September and October 2021 from the university and college of agriculture in Kerbala. After being validated by a taxonomist, and being washed with water, the leaves were dried in the shade. They ground the dried leaves into fine particles using a dry grinder and then sieved them. Using 2 L of distilled water, 1000 g of powdered leaves were extracted for 8 hours while being stirred frequently. The extract was centrifuged, the supernatants evaporated in a vacuum rotary evaporator, and the leftovers were refrigerated for subsequent experiments.



Figure (1): Photographs of *Callistemon viminalis*

Animals

At the University of Karbala's College of Veterinary Medicine, male Wister albino rats weighing between 150 and 200 g were bought from the animal house. Under typical lab circumstances (12 h of alternate day and night cycles, with rooms air-conditioned at 25–28 °C), animals were housed in animal cages. Prior to the start of the experimental treatments, rats spent a week getting used to the lab environment. Rats had unlimited access to water and regular pellet food.

Chemicals

This experiment's materials were all of the analytical variety. Silymarin, paracetamol (E. Merck) (Sigma Chemical Co.). Diagnostic kits for assessment of serum transaminases (ALT, AST), alkaline phosphatase (ALP) enzymes, and serum bilirubin as well as antioxidants enzyme i.e. catalase and superoxide dismutase were manufactured by Bio lab.

Experimental Design

After adaptation, twenty-four animals were split into four groups of six at random, as follows: 1st Group: rats in this group were administered distilled water and served as the control group. 2nd Group: Rats in this group received paracetamol at a dose of 2 g/kg once daily for one week to induce liver injury, while rats in the 3rd group were administered AECV via oral gavage at a dose of 200 mg/kg B.W. for four weeks following the administration of paracetamol. Finally, following the administration of paracetamol, the 4th group was given silymarin orally as a reference hepatoprotective drug at a dose of 100 mg/kg B.W.



Biochemical and antioxidant enzyme parameters

Animals were denied nourishment for a whole night before being sacrificed, first through the use of anesthetic medicines i.e. ketamine and xylazine, then through cervical dislocation, and then blood was drawn from each group for assessment of the levels of serum ALT, AST, ALP, and TB, in addition to antioxidants parameters i.e. SOD and CAT that were measured by using commercial kits (Bio Lab).

Histological assessment

The livers were rapidly removed when the animals were sacrificed, and small pieces of each liver were kept in 10% formalin and processed for paraffin embedding using the industry-standard micro procedures. Hematoxylin and eosin (H&E) were used for staining of sections (5 μ m thick) of liver tissues to assess the histopathological changes under a light microscope.

Statistical Analysis

GraphPad Prism version 9.0 for Windows was used to analyze all data, which are presented as mean standard error of the mean. Prior to conducting a comparative statistical analysis, normality tests utilizing the D'Agostino and Pearson normality test and analysis of variance (ANOVA) with the multiple comparisons test of Turkey were conducted. $P \leq 0.05$ was considered significant.

Results and Discussion

Biochemical parameters

Experiments were conducted to assess some biochemical parameters in paracetamol –induced liver damage in male rats. It was revealed that the levels of ALT, AST, ALP, and TB were significantly increased in the paracetamol treated group compared to control group ($P < 0.0001$). ACEV and Silymarin significantly decreased AST, ALT, ALP, and TB levels compared to the paracetamol group ($P < 0.0001$) (figure 2). Furthermore, there was a significant difference in AST and ALP in the Silymarin-treated group compared to ACEV ($P = 0.001$ and $P = 0.03$ respectively) following paracetamol treatment (Figure 2).

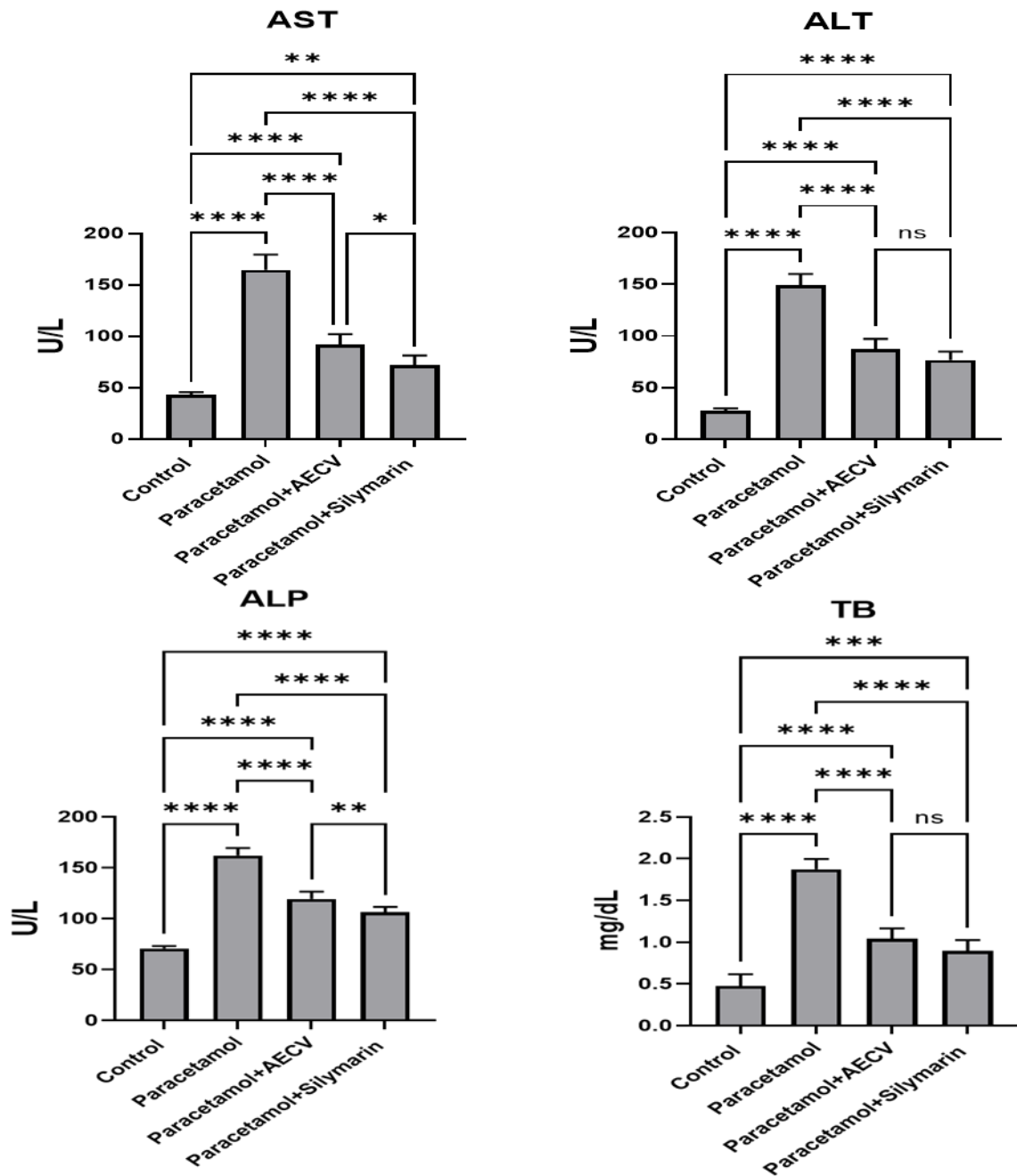


Figure (2): Some biochemical levels following treated groups in male rats

Antioxidant parameters

Experiments were conducted to assess some antioxidant parameters in paracetamol-induced liver damage in male rats. It was shown that the levels of both CAT and SOD were significantly decreased in the paracetamol treated group compared to the control group ($P < 0.0001$). ACEV and Silymarin significantly increased AST, ALT, ALP, and TB levels compared to the paracetamol group ($P < 0.0001$) (figure 3).

Additionally, the level of SOD was significantly different in the silymarin treated group compared to the ACEV treated group ($P=0.04$) (figure 3).

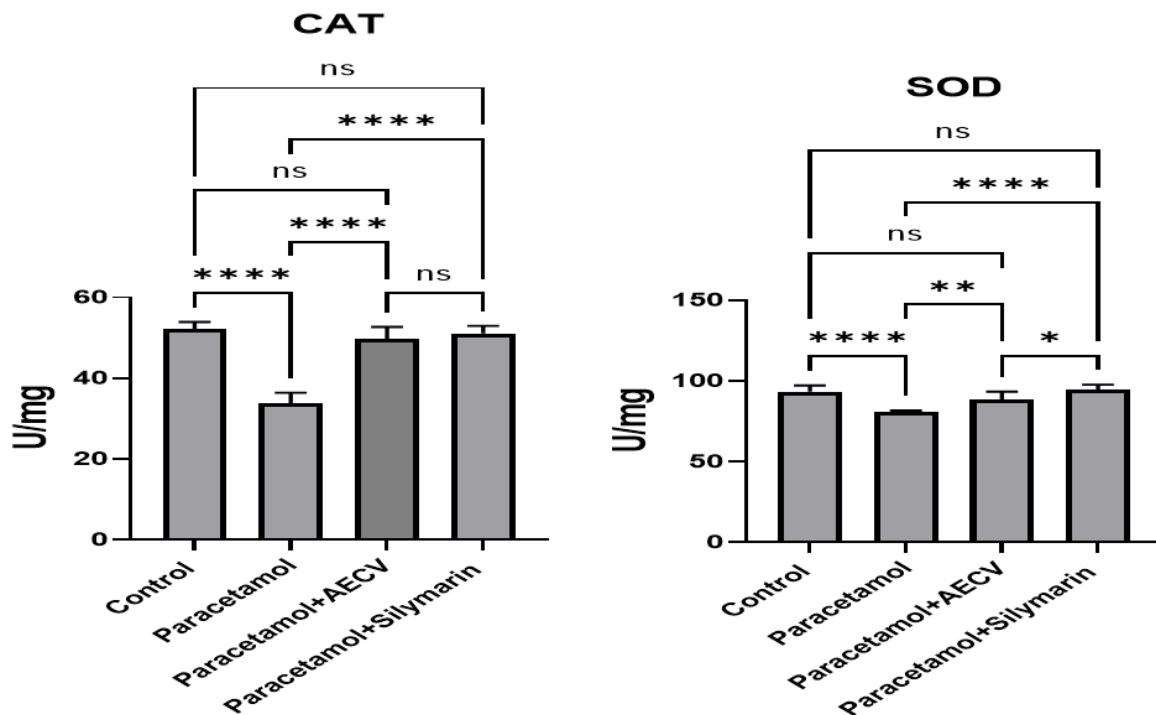


Figure (3): Some antioxidant enzyme levels following treated groups in male rats

Histopathological studies of liver section

Figure 4 (A) shows a normal hepatic anatomy manifested by normal hepatocyte cords (black arrows) around the central vein (red arrow) and normal sinusoids (white arrow) in the control group's histopathological section of liver. While, the histopathological changes in the liver section of the paracetamol induced liver injury group, showed a severely congested central vein (black arrow), there was also, a significant infiltration of mononuclear inflammatory cells (red arrow) around the central vein and marked fibrous connective tissue bundles (white arrow) around the blood vessels, as well as fibroblast infiltration (yellow arrow) Figure 4 (B). A photomicrograph of the liver from the paracetamol-induced liver injury group revealed significant fatty degeneration (cytoplasmic vacuoles in hepatocytes) (black arrow), mild hemosiderin pigments (red arrow), and some hepatocytes with deep stained nuclei, indicating necrosis (white arrow in figure 4 (C)). Interestingly, sections of liver from the treated group, revealed mild to moderately congested central veins (black arrows), significant mononuclear inflammatory cell infiltration (red arrow), and mild hepatocyte fatty vacuolation (white arrows) (Figure 4 (D)). Furthermore, sections of liver from the treated group, revealed mild to moderate infiltration of inflammatory cells in the por-

tal area (black arrow) , slight degenerative changes on hepatocytes (white arrow), and marked hepatocyte cords (yellow arrow) figure 4 (E).

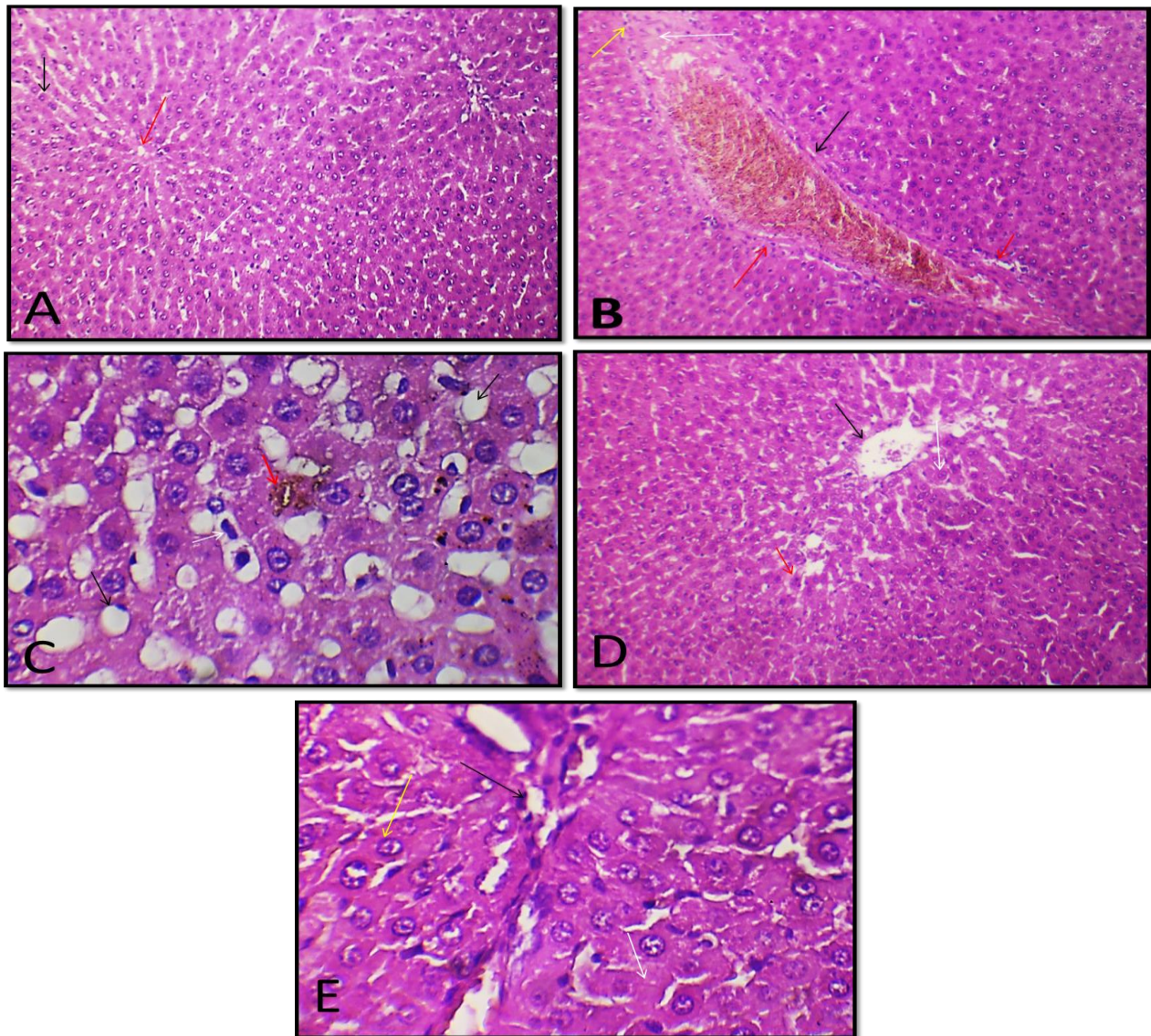


Figure (4): Histopathological images of liver sections

The experiments carried out in this study were conducted to examine the hepatoprotective effects of *Callistemon viminalis* in rat induced paracetamol toxicity. Paracetamol was used to induce liver toxicity at a dose of 2g/kg B. Wt. The data presented here show that taking paracetamol at this dose can result in serious liver damage. This was seen from the data obtained from some biochemical and antioxidant parameters as well as the histopathological changes for the liver sections stained with the standard histopathological stain, i.e., hematoxylin and eosin stain. Importantly, a significant finding was that administration of ACEV at a dose of 200 mg/kg B.W.T. demonstrated hepatoprotective and antioxidant action against paracetamol-induced liver damage. This might be attributed to the phytochemical screening of AECV. It has been shown that the phytochemical screening of AECV reveals triterpenes, ster-



ols, flavonoids, phenols, and saponins, and that these antioxidant phytochemicals of AECV might contribute to its hepatoprotective activity. According to a study by [14], *Callistemon viminalis* leaf extract exhibited antioxidant activity on par with that of common antioxidants like gallic acid. The total extracts from the numerous parts of *Callistemon viminalis* also demonstrated potential antioxidant action, comparable to that of the industry-standard antioxidant, ascorbic acid, according to [15].

This study's findings highlighted the fact that AECV was clearly protective against paracetamol damaging effects on the rats' livers. AECV protective efficacy at a dose of 200 mg/kg/day is also extremely comparable to that of silymarin at a dose of 100 mg/kg in terms of hepatotoxicity indicators and histological findings

References

- 1) Muriel P. (2007) Cytokines in liver diseases. In: Sahu SC editor. Hepatotoxicity: From genomics to in vitro and in vivo models, West Sussex, England; Wiley: 2007 pp. 371–389.
- 2) Cichoż-Lach, H.; Michalak, A. (2014) Oxidative stress as a crucial factor in liver diseases. *World J. Gastroenterol.*, 20, 8082–8091.
- 3) Chiang, J. (2014) Liver Physiology: Metabolism and Detoxification. *Pathobiol. Hum. Dis.*, 1770–1782.
- 4) Wahlang, B.; Jin, J.; Beier, J.I.; Hardesty, J.E.; Daly, E.F.; Schnegelberger, R.D.; Falkner, K.C.; Prough, R.A.; Kirpich, I.; Cave, M.C. (2019) Mechanisms of Environmental Contributions to Fatty Liver Disease. *Curr. Environ. Health Rep.*, 6, 80–89.
- 5) Rao GM, Rao CV, Pushpangadan P, Shirwaikar A. (2006) Hepatoprotective effects of rubiadin, a major constituent of *Rubia cordifolia* Linn. *J Ethnopharmacol.* 103(3):484-490
- 6) Hemphill TLC, Cobiac L. (2006) Health benefits of herbs and spices: The past, the present, the future. *Med J Aust* , 185: S4–S24.
- 7) Devaraj S, Ismail S, Ramanathan S, and Yam FM . Investigation of Antioxidant and
- 8) Hepatoprotective Activity of Standardized *Curcuma xanthorrhiza* Rhizome in Carbon
- 9) Tetrachloride-Induced Hepatic Damaged Rats. *Scientific World Journal* 2014, 1 -8.
- 10) Abdelhady, M. I., Motaal, A. A., & Beerhues, L. (2011). Total phenolic content and antioxidant activity of standardized extracts from leaves and cell cultures of three *Callistemon* species. *American Journal of Plant Sciences*, 2(6), 847.



- 11)** Tiwari, U., Jadon, M., & Nigam, D. (2014). Evaluation of antioxidant and anti-bacterial activities of methanolic leaf extract of *Calistemon viminalis*. *International Journal of Pharmaceutical Sciences and Business Management*, 2, 1-12.
- 12)** El Dib, R. A., & El-Shenawy, S. M. (2008). Phenolic constituents and biological activities of the aerial parts of *Callistemon viminalis* (Sol. Ex Gaertner) G. Don ex Loudon. *Bull. Fac. Pharm*, 46, 223-235.
- 13)** Abd, J. (2012). Studying of antibacterial effect for leaves extract of *Callistemon viminalis* in vitro and vivo (urinary system) for rabbits. *Journal of kerbala university*, 8, 246-254.
- 14)** Abdelmalek, E.M., Ramadan, M.A., Darwish, F.M. et al.(2021) *Callistemon* genus- a review on phytochemistry and biological activities. *Med Chem Res* 30, 1031–1055 .
- 15)** Ye H, Nelson LJ, Gómez Del Moral M, Martínez-Naves E, Cubero FJ.(2018) Dissecting the molecular pathophysiology of drug-induced liver injury. *World J Gastroenterol*.24(13):1373-1385.
- 16)** Zubair, M., Hassan, S., Rizwan, K., Rasool, N., Riaz, M., Zia-Ul-Haq, M., & De Feo, V. (2013). Antioxidant potential and oil composition of *Callistemon viminalis* leaves. *The Scientific World Journal*.
- 17)** Gohar, A. A., Maatooq, G. T., Gadara, S. R., & Aboelmaaty, W. S. (2013). One new pyrroline compound from *Callistemon viminalis* (Sol. Ex Gaertner) G. Don Ex Loudon. *Natural product research*, 27(13), 1179-1185.